

So you want to be an implant dentist...?

Nilesh R Parmar gives some pointers to newly-qualified dentists looking to develop their interest in dental implants

AT THE moment there is a myriad of possibilities available to the young dentist in how to get into implant dentistry. Keep in mind that there is a GDC requirement that whatever training programme you embark upon follows the FGDP guidelines for implant training. These have been recently updated for 2012 and now stands as an eight-page document available from the Royal College of Surgeons website. One key thing to point out is that the document states, 'Dentists undertaking such treatment [complex] should have been trained and assessed by a suitably competent and experienced mentor with an appropriate structured programme.'

This means that before placing dental implants you must have undergone some form of structured training, ideally with a mentor in place, with some form of an exit exam. The days of a two-day course in Europe are probably long gone. Dentists must now show that they have undertaken the necessary training before placing dental implants.

Nilesh R Parmar

BDS (Lond) MSc (ProsthDent) MSc (ImpDent) CertOrtho was voted Best Young Dentist in the East of England in 2009 and runner up in 2010. He was shortlisted at the Private Dentistry Awards in the category of outstanding individual in 2011. Nilesh has a masters degree in prosthetic dentistry from the Eastman Dental Institute and a masters degree in clinical implantology from King's College London. He is one of the few dentists in the UK to have a degree from all three London Dental Schools and recently obtained his certificate in orthodontics from Warwick. His main area of interest is in dental implants and Cerec CAD/CAM technology. Nilesh runs a successful five-surgery practice close to London and is a visiting implant dentist to two central London practices. He also offers training and mentoring to dentists starting out in implant dentistry (details on website below). www.drmileshparmar.com

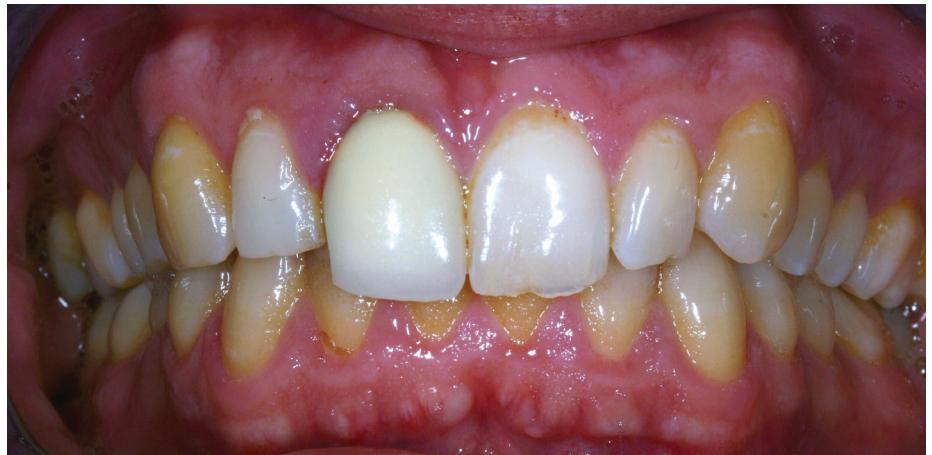

Figure 1: Initial presentation

Be it part time, full time or modular, you have plenty of options for where you learn implant dentistry. Once it's all completed, then it's time to actually start placing implants. So what do you need to do? Well the first thing you need is to be working in a practice with a good patient base to advertise your newfound skills. If you have any associates working for/with you, they, along with your staff, need to be briefed on your capabilities.

Imagine the scenario: you've had the patient in the chair, discussed implant treatment with them and quoted a reasonable fee. Once that patient says 'yes', that's when you start to get a bit worried. There is no turning back now; you are destined to place your first implant in practice.

In order to do this you will need: surgical instruments; a well-trained nurse; a surgical drape kit; an implant motor; and an implant kit. Which implant system you choose is ultimately down to personal preference. With the recent bankruptcy of a few budget implant systems, I would recommend you choose wisely. The mainstream systems bring with them a guarantee of good quality research and compatibility. They also have a cost premium. The lesser-known systems are the opposite, they have limited research but are much cheaper. As a dental professional it's up to you to decide

which implant system to partner with (I made my choice a long time ago). As a young dentist, my words of advice would be to put yourself in the patient's shoes. If you were having something surgically fused with your body, which implant would you like used? Based upon your answer to that question, you'll be able to choose the ideal implant system for you.

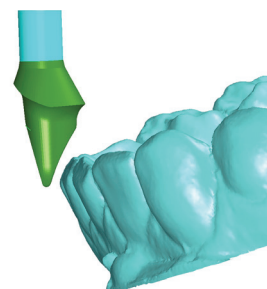
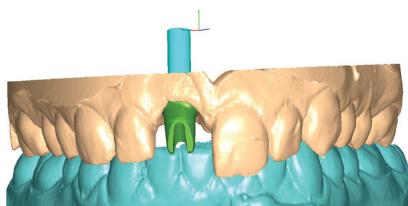
Case study

This is a typical implant case, a patient presents with an upper central with a history of periapical infection (Figure 1). Replacing central incisors with a history of endodontic treatment is commonplace in implant therapy. Root fracture, due to trauma with post crowns, is a common occurrence. Unfortunately, in these circumstances re-endodontic treatment cannot be carried out and extraction is indicated.

It is important to extract upper anterior teeth very carefully. I like to use periostomes to initiate loosening of the tooth by severing the periodontal ligament. I then use a combination of ultra-thin luxators and very precise root forceps to slowly rotate the tooth out. Once the tooth has been removed, the buccal plate needs to be inspected, a thin buccal plate will warrant some form of augmentation in order to ensure maintenance of the bony envelope for implant placement later on. Every implant dentist

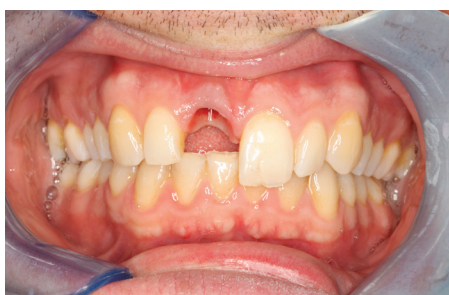

Figure 2: Soft tissue developed using a temporary crown



Figures 3a and 3b (above and right): Atlantis virtual abutment design

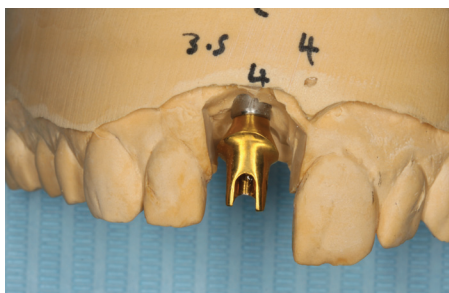


Figure 4: Atlantis Goldhue abutment (Astra Tech)

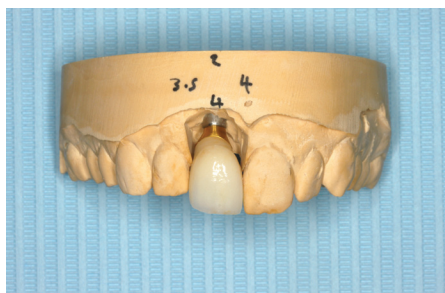


Figure 5: E.max crown on working model

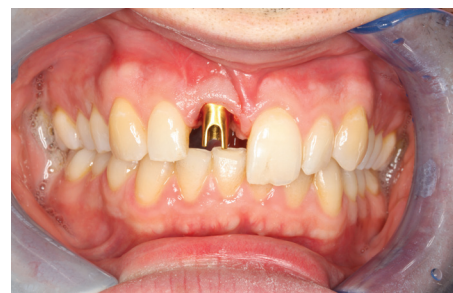

Figure 6: Atlantis Goldhue abutment in situ

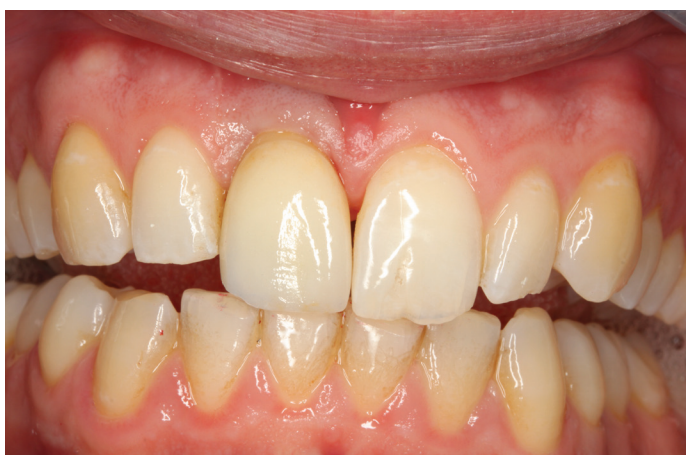

Figure 7: Final presentation

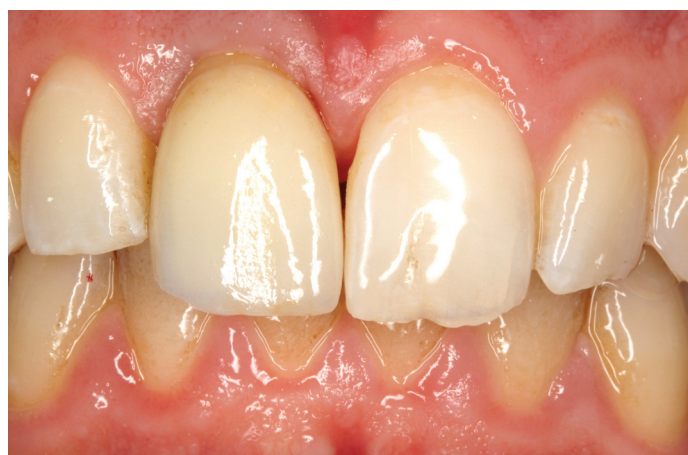

Figure 8: Close up of final crown, note gingival zeniths

appears to have his or her own special ‘potion’ to magically form bone from an extraction socket. I find that just placing a sterile collagen plug and letting nature take its course tends to give me good results. Patient selection is key, along with preparing them for a bone graft later on if the bone levels aren’t sufficient.

In this case, the tooth was atraumatically extracted using periostomes and very light forces. Upon removal the socket was curetted out and a collagen plug placed. An immediate partial denture was fitted with only very slight socketing. I like to adjust the pontic so that it supports the labial soft tissue, combined with occlusal/cingulum rests on adjacent teeth, which stops the pontic digging into the socket on biting. After two months of healing, an Astra Tech implant was placed with some guided bone regeneration needed on the labial surface.

I achieved good primary stability, so a healing abutment was placed at the time of implant placement. After two months of healing, a temporary crown was made to help develop the soft tissues. This is left in place for six weeks (Figure 2). After this time another fixture level impression is taken and an Astra Tech Goldhue Atlantis abutment is made along with an E.max crown (Figures 3-6).

These cases can seem very challenging, as it’s in an area of the mouth that everyone can see - the aesthetic zone. If handled carefully, with good surgical techniques and an understanding of the prosthetic needs, then a good result can be obtained (Figures 7 and 8). I learnt how to do these cases by watching American periodontists place implants, then reading about how the prosthodontists would go about restoring them. It took many hours of

study and thinking things through in my head before I got to this stage. However, as with all things that require a lot of effort, it’s certainly worth it.

Read the updated Training Standards for Implant Dentistry document at: www.fgdp.org.uk/content/news/updated-training-standards-for-implant-dentistry.ashx