

# A challenging self-referral

Nilesh Parmar presents a case that highlighted a good example of the cement-retained versus screw-retained debate in implant dentistry

## Introduction

Implant dentistry isn't easy. If it were, everyone would be doing it. What I have found is that, that even after completing a two-year masters degree in clinical implantology, I am still learning new things on a daily basis. One thing that I have noticed is that I am seeing a lot more cases where the patient is unhappy with the work carried out by their own dentist. Now as human beings, it's very easy to point the finger and blame the dentist. I always try to keep an open mind in situations like this; we have all had difficult patients to treat where the final outcome may not have been ideal.



Dr Nilesh R Parmar BDS (Lond) MSc (ProsthDent) MSc (ImpDent) Cert. Ortho was named Best Young Dentist in the East of England at the Dentistry Awards in 2009 and runner-

up in 2010. He was shortlisted at the 2011 Private Dentistry Awards in the category of Outstanding Individual. Nilesh has master degrees in Prosthetic Dentistry from the Eastman Dental Institute and in Clinical Implantology from King's College London. He is one of the few dentists in the UK to have a degree from all three London Dental Schools and has recently obtained his Certificate in Orthodontics from Warwick University. His main area of interest is in dental implants and Cerec CAD/CAM technology. Nilesh runs a successful five-surgery practice close to London and is a visiting implant dentist to two central London practices. He also offers training and mentoring to dentists starting out in implant dentistry. More information can be found at [www.drnileshparmar.com](http://www.drnileshparmar.com). Twitter: @NileshRParmar. Facebook: Dr Nilesh R. Parmar.



## Education aims and objectives

To gain a greater understanding of the merits of screw-retained implants compared to cement-retained restorations, and how this knowledge helped solve a complex case on a patient unhappy with previous treatment

## Expected outcomes

To be able to see how a challenging multiple implant case can be overcome by carefully studying and replacing previous unsuccessful implant placements, including surgical removal of one failed implant and fabricating three new upper and lower screw-retained bridges

## Patient's main complaint

This is one such case, which was a self-referral from the patient. He had multiple implant placements by his own dentist and was unhappy with the final restorations. The patient reported that the bridges had come away from the abutments more than 15 times in the last year and a half. He had also been experiencing some discomfort in the upper left quadrant for some time.

## Presenting symptoms

The patient had the implants placed two years previously under local anaesthetic. The implants were Nobel Biocare Select replace implants, with bi-lateral sinus lifts. The patient reported previous failures in the upper left quadrant but reported that the surgical side of the procedure was without incident.

## Medical history

The patient suffers from mild arthritis. He is currently taking no medication and is a non-smoker.

## Dental history

Regular attender. The patient's old radiographs and notes were obtained from his previous dentist. From this a chronology of the previous treatment was worked out. This included:

- Extraction of the UL3, UL6 & LL8
- Bi-lateral sinus floor elevation
- Implant placement in the UR4, UR7, UL3, UL6, LL5 & LL7 regions
- Restorations of the upper implants with 2 fixed bridges and the lower left implants with fixed individual crowns.

The implants placed in the UL3 and UL6 sites were immediate placements. Unfortunately they both failed and the dentist was forced to remove these. After a three-month healing period, two more implants were inserted in the UL3 and UL7 sites. These healed without incident and the patient was restored.

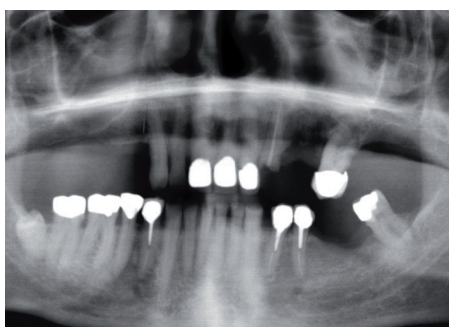
## Intra-oral examination, clinical findings

Intra-orally the patient presented with calculus around the lower anterior teeth, with adequate oral hygiene. The patient exhibited signs of occlusal disease and moderate wear. He reported that he was unable to clean underneath the bridges and noted a bad smell coming from the ULQ.

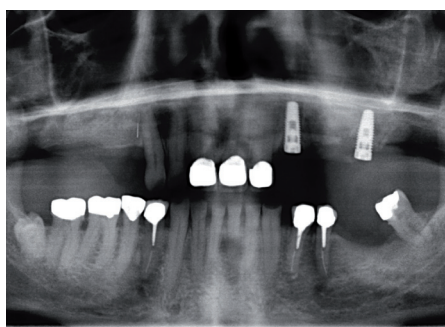
The implants were Nobel Replace Tapered Groovy implants, with Bio-Oss and Bio-Guide being used in the sinus lifts.

The upper implant bridges were cement-retained, porcelain-fused-to-metal restorations. Both bridges had a slight rock when pressure was applied on the mesial or distal pontics indicated they weren't seated correctly, or did not fit on the abutments. Occlusal contacts were very heavy on the anterior pontics, with posterior interferences on excursive movements of the mandible.

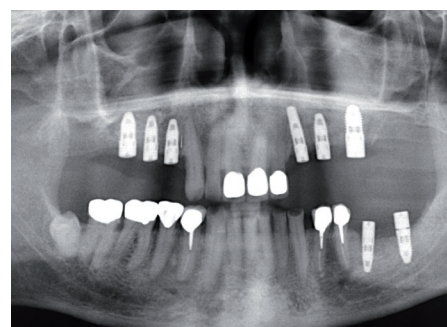
The probing depths around the implants were 2-3mm except for the UL7 implant which was in excess of 7mm. This implant had failed and was being held in place by its attachment to the bridge. At this point it was decided to take a full volume CBCT scan to assess the issue in the UL7 implant, along with gauging bone levels and pathology around the



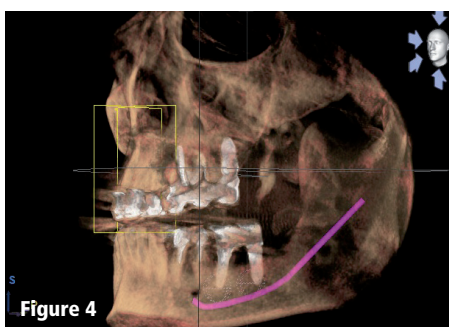
**Figure 1:** Pre-op OPG



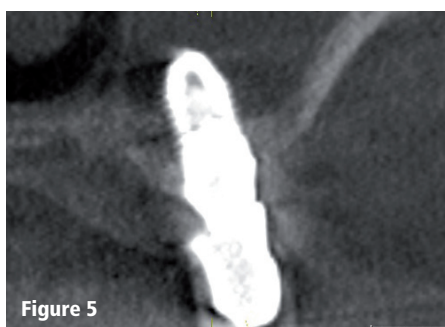**Figure 2:** Immediate implants which failed



**Figure 3:** Post-op OPG after UL implants were removed and re-done

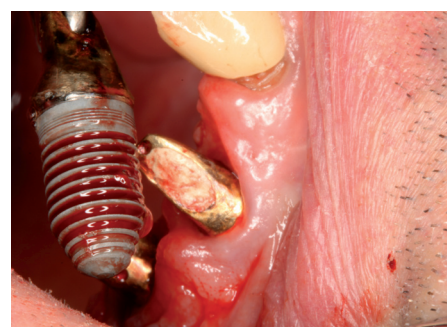


**Figure 4**

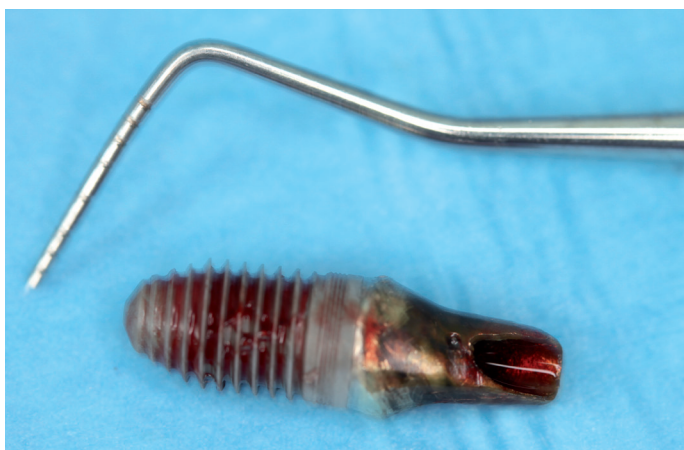

**Figure 5**

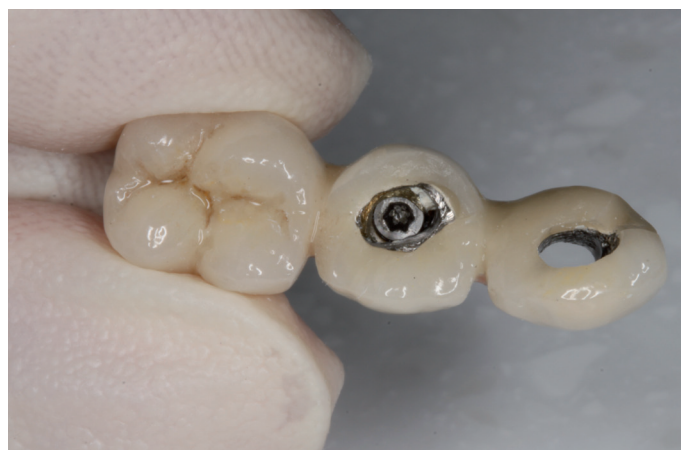**Figures 4-5:** CBCT images. Figure 5 shows failed implant UL7



**Figure 6:** Surgical removal of the UL7 failed implant



**Figure 7:** Extracted UL7 implant



**Figure 8:** Drilling to access the screw hole of the old bridge to convert it into a screw-retained restoration

remaining implants.

The CBCT showed severe bone loss around the UL7 with very little bone formation in the sinus around the implant. The UL7 implant has failed and would require surgical removal. The remaining implants appeared to be sound, but of interest, the implants placed in the lower left quadrant were very close to the lingual cortical plate of the mandible.

### Treatment aims

The aims of my treatment were to:

1. Remove the infected/failed implant and repair the subsequent oral-antral fistula.
2. Convert the existing cement-retained restorations into screw-retained restorations for the interim.

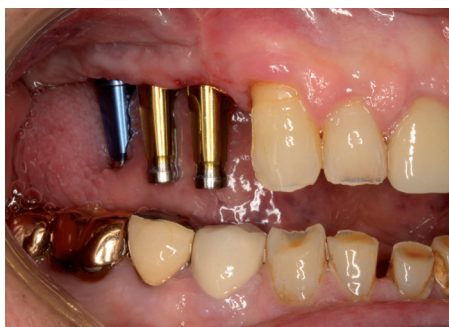3. Fabricate three new upper and lower screw-retained bridges which are easily cleansable by the patient.

### Treatment carried out

The immediate problem was the implant in the UL7 site. The patient was numbed up and a sterile surgical procedure was carried out to remove the Nobel Select Replace Groovy 6mm super wide implant. The implant had lost all osseointegration and was only held in place via fibrous encapsulation. The implant was removed using mosquito forceps, the resulting OAF was repaired by removing the fibrous tissue, thoroughly irrigating the site with sterile saline and then placing a double membrane over the hole. I then buccally

advanced the flap and closed everything off with a continuous suture. The patient was placed on a combined Amoxicillin 500mg and Metronizadole 400mg tds for seven days. The patient was also given strict instructions not to blow his nose, carry out any vigorous exercise and generally lead a sedentary lifestyle for the next two months. The site healed without incident.

Whilst this site was healing the patient's bridges were made into screw-retained restorations; this would allow the patient to eat and chew with confidence whilst the treatment was progressing, whilst allowing easy removal. The bridges were removed and permanently cemented to the abutments with screw access holes made through the ceramic. These were



Figures 9-10: Closed tray impressions

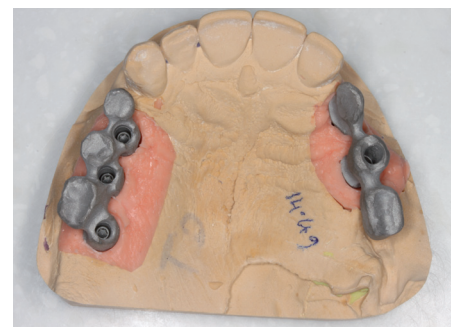
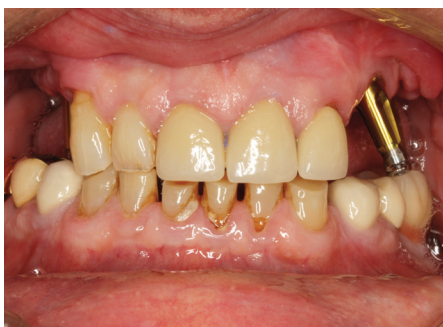
Figure 11: Bridge framework

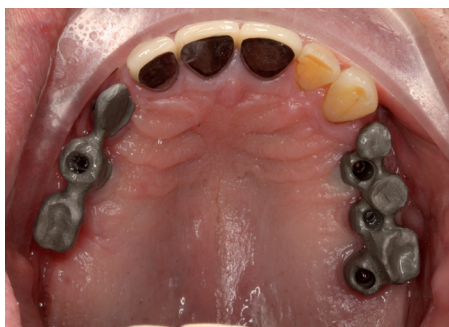

Figure 12: Bridge framework in-sit

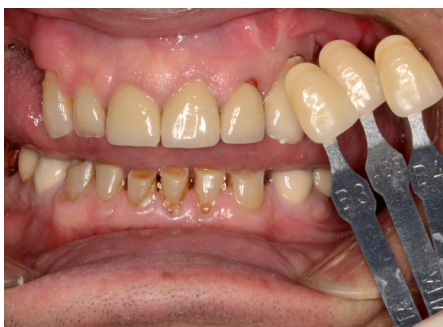

Figure 13: Shade taking with three tabs

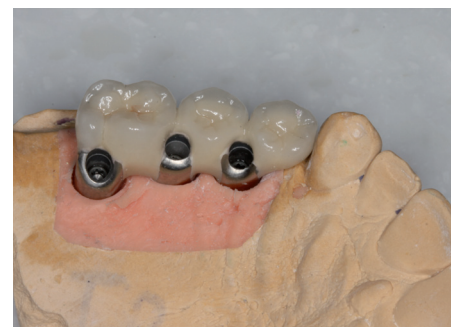

Figure 14: Finished bridge

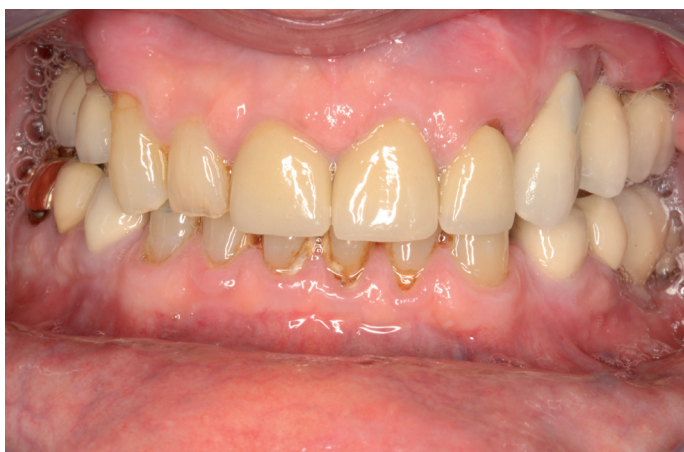

Figure 15: Fit anterior view

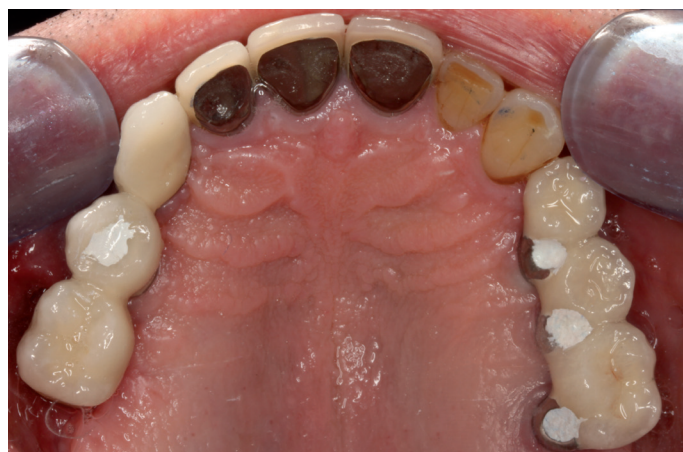

Figure 16: Fit occlusal view

then re-attached to the implants, whilst the surgical site healed.

After a healing period of six weeks, soft tissue closure had occurred over the UL7 site. Fixture level open tray impressions were taken of all seven implants and bridge frameworks were made. Due to the patient having trouble with the previous bridges de-cementing, it was decided that all the resulting bridges would be screw-retained restorations for greater long-term predictability and easy retrieval.

The frameworks were tried in and assessed for porcelain clearance and passivity of fit. Once the framework was verified the bridges were completed. The patient was made aware that, due to the implant positioning and bone loss, the teeth on the bridges would begin

further up the gum than his own teeth, and the composite covering the screw hole may be visible under close scrutiny. As the patient was primarily concerned with function he accepted this compromise.

The final bridges and fitted to 35Ncm and baseline radiographs were taken. The patient was also made a nighttime occlusal splint due to concern over his parafunction.

### Long-term outlook

The patient has since been seen for two reviews, and has been problem-free for over six months. He has not had any further screw loosening issues, and is now able to confidently eat his food. The patient's parafunction has been reported to have gone, as it was possibly related to the stress of the previous bridges.

### Discussion

This case was a good example of the cement-retained versus screw-retained debate in implant dentistry. The author's personal preference is to always attempt to obtain a screw-retained restoration for the patient. There is no cement to clear away, the restoration is retrievable and there is utmost certainty that it has correctly seated. In order to obtain an occlusally positioned access hole, a well-planned restoratively driven implant protocol needs to be carried out. In certain cases, it is impossible to place the implant in the ideal situation and a compromise may need to be reached. In the anterior maxilla, and in highly aesthetic cases, the use of custom made abutments, along with zirconia and all ceramic lithium disilicate crowns, maybe necessary.

Care to comment? @AesDenToday