

DIGITAL DENTISTRY

CBCT in implant dentistry

Dr Nilesh Parmar presents a case study using CBCT to aid in implant dentistry

sponsored by **HENRY SCHEIN®**
ConnectDental™
 DIGITAL RESTORATIVE SOLUTIONS FOR PRACTICES & LABORATORIES

Implant treatment in the anterior mandible has favourable long-term success rates when compared with other areas of the mouth (Gokcen-Rohlig et al., 2009). Placement of dental implants in the inter-foraminal area is considered a safe and predictable procedure. However, perforation of the lingual cortical plate can result in a profound and potentially life-threatening sublingual bleed (Pelayo, 2008). The blood supply to this area is provided by the submental, sublingual and mylohyoid arteries, which if perforated, may set off a massive internal haemorrhage in the floor of the mouth. Although rare, this can ultimately cause protrusion of the tongue, resulting in airway obstruction and necessitating surgical intervention. It has been suggested by Tepper et al. (2001) that computerised tomography imaging of this area is warranted for visualising 3D bone anatomy prior to surgery, thereby reducing the possibility of surgical instrumentation in this sensitive area.

In this case report, I shall show how cone beam computed tomography (CBCT) coupled with chairside diagnostic imaging could help in planning, simplifying and executing implant placement in the anterior mandible.

Patient history

A 44-year-old female patient who was undergoing long-term periodontal treatment presented with mobile and painful lower incisors. She exhibited very good oral hygiene but with a periapical area and mobility associated with tooth UR4 and grade two mobility of her lower incisors. The patient described difficulty and embarrassment when eating owing to the movement of her lower teeth and wanted a fixed solution.

Clinical examination

The patient had a lightly restored dentition with a thin gingival biotype. As previously mentioned, her oral

hygiene was good and she was a non-smoker (gave up 11 years previously). She exhibited bilateral canine guidance with no evidence of any para-function. Her basic periodontal examination scores were 312/231.

Treatment options

Owing to the patient's history of periodontal disease and associated mobility, she was aware that some form of replacement was necessary. The patient did not want a removable restoration and preferred a fixed solution. In this area of the mouth, either fixed bridgework or an implant-retained prosthesis was possible. After discussing the options and highlighting the increased risk of peri-implantitis in patients with previous periodontal disease (Esposito 2006), the patient opted for a fixed implant-retained solution. The treatment was to be planned in such a way that if she lost her posterior molars in the future, a full-arch fixed prosthesis could be made after subsequent implant placement.

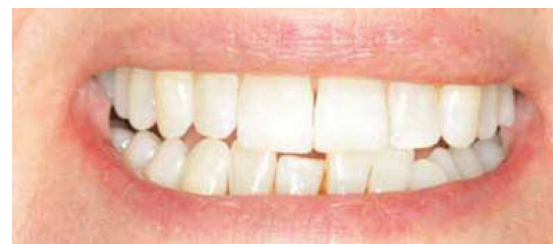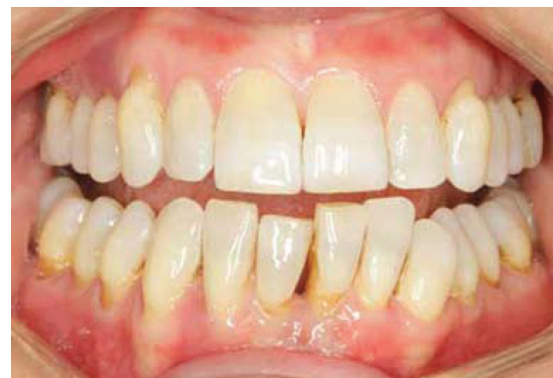Treatment plan

Treatment was to be carried out as follows:

- 1 Continuation of periodontal treatment and oral hygiene advice
- 2 CBCT Galileos (Sirona) scan to assess bone height, bone profile and associated anatomy
- 3 Extraction of all four lower incisors and tooth UR4
- 4 Placement of two Slactiva implants (Straumann)
- 5 Restoration with a screw-retained four-unit porcelain-fused-to-metal bridge.

CBCT

It was decided to take a full-volume CBCT scan to further assess the upper teeth and tooth UR4 for future implant replacement. The CBCT scan showed excessive bone loss around the anterior incisors with a small area of periapical radiolucency around tooth LL1. A cross-sectional view showed thick, well-developed cortical plates with very



Figures 1 & 2 Pre-op presentation

little lingual concavity. Owing to the good bone height and minimal pathology, immediate implant placement was planned.

Due to the patient's bone loss, the lower incisors had drifted, giving a less than desirable tooth position. One of the patient's main complaints were the gaps that had

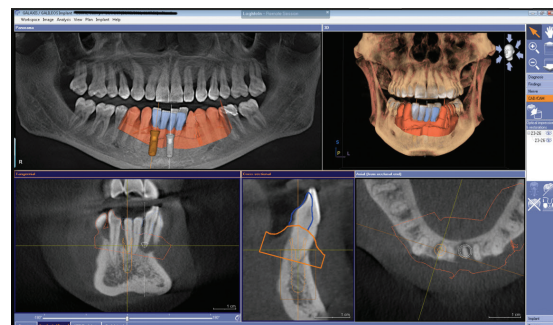


Figure 4 CBCT scan with a Cerec Bluecam overlay showing ideal final result

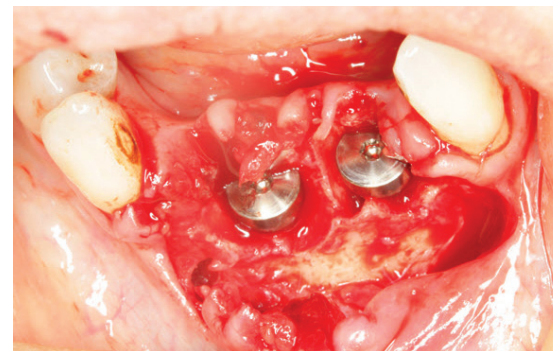


Figure 5 Stage 1 of implant placement, with healing abutments in place



Dr Nilesh R. Parmar BDS (Lond) MSc (ProsthDent) MSc (ImpDent) Cert.Ortho was voted Best Young Dentist in the east of England in 2009 and runner up in 2010. He was shortlisted at the Private Dentistry Awards for Outstanding Individual 2011 and received highly commended for Best Dentist South at the 2013 Dental Awards. Nilesh has a masters degree in prosthetic

dentistry from the Eastman Dental Institute and a masters degree in Clinical Implantology from King's College London. He is one of the few dentists in the UK to have a degree from all three London Dental Schools and has recently obtained his certificate in orthodontics from Warwick University. His main area of interest is in dental implants and Cerec CAD/CAM technology. Currently studying for his MBA, Nilesh runs a successful seven-surgery practice close to London and is a visiting implant dentist to two central London practices. Nilesh has a never-ending passion for his work, attention to detail and his belief that every patient he sees should become a patient for life. He offers training and mentoring to dentists starting out in implant dentistry, more information can be found on his website www.drnileshparmar.com.

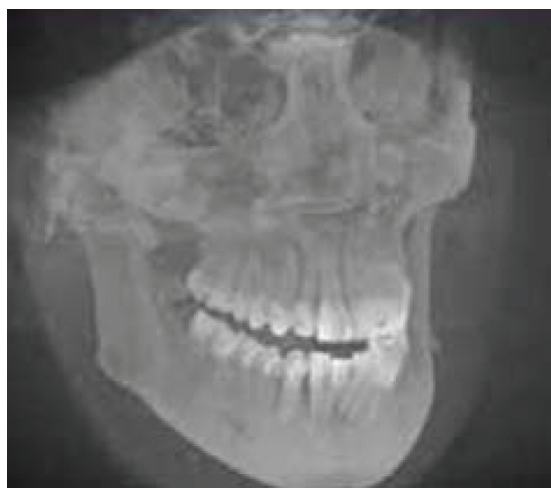

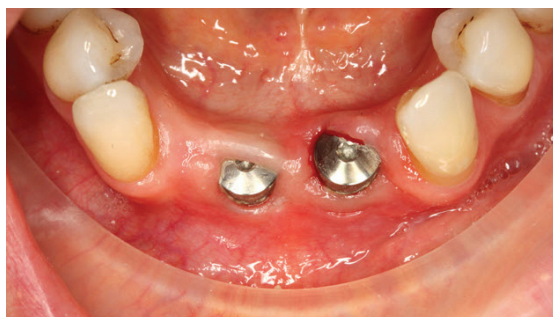Figure 3 Maximum intensity projection using Sirona Galileos



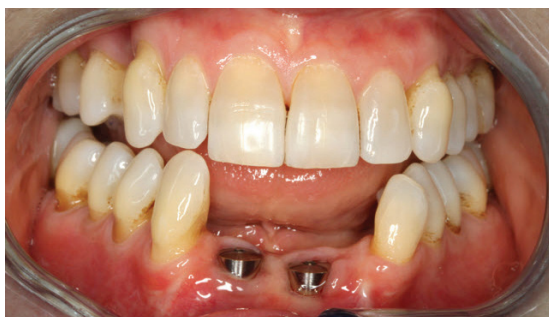Secure, encrypted communication

The General Dental Council Standards for the Dental Team 2013 states:
 'If you are sending confidential information electronically,
 you should ensure that it is encrypted.'

HENRY SCHEIN®
ConnectDental™
 DIGITAL RESTORATIVE SOLUTIONS FOR PRACTICES & LABORATORIES



Figures 6 & 7 Presentation at eight weeks



Figures 8 & 9 Laboratory-made screw-retained porcelain bridge on Straumann Synoceta abutments

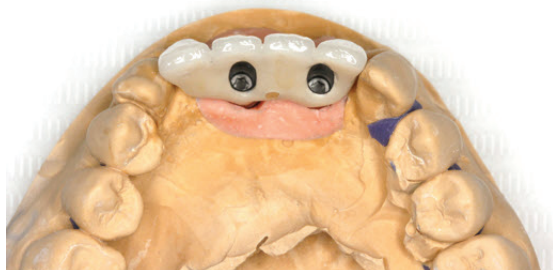

Figure 10 The bridge

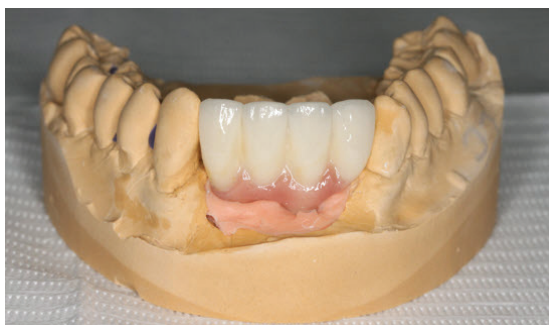

Figure 11 Appearance at fit

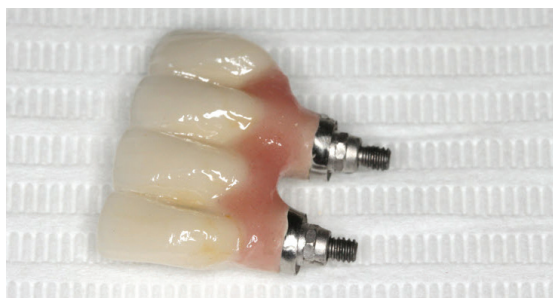

Figure 12 Pre-op presentation

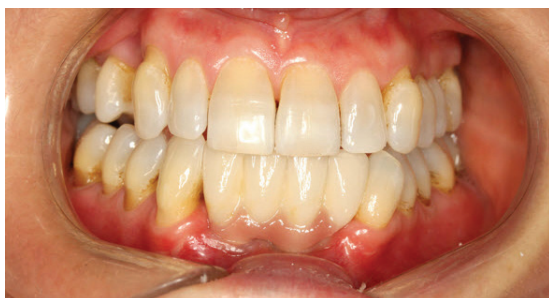

Figure 13 CBCT scan with Cerec integration

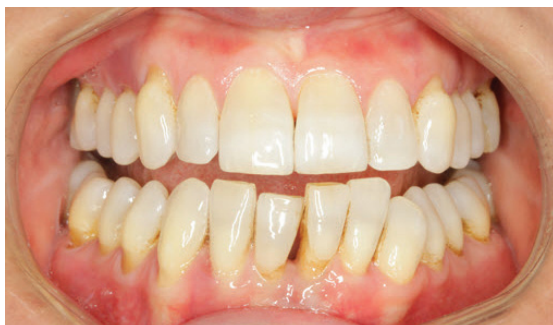

Figure 14 After eight weeks of healing

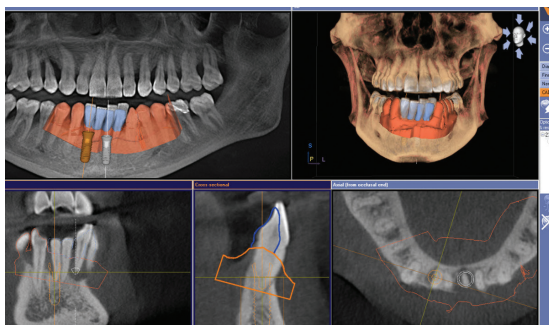
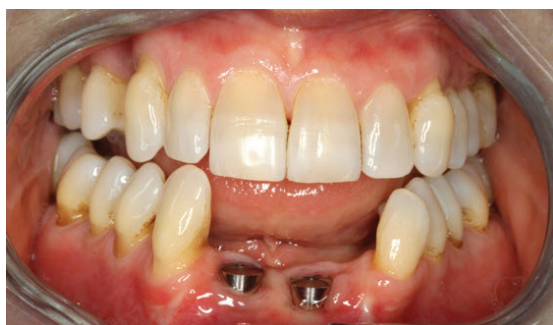
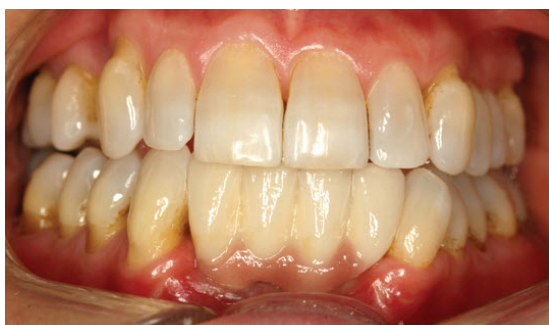
Figure 15 Insertion of final bridge



Figures 16 & 17 Appearance at one-month review



appeared between the lower incisors and the uneven appearance of the incisal edges.

To aid implant placement in the correct angulation a Cerec Bluecam image was taken and manipulated so that the lower tooth positions were in harmony with the rest of the dentition. This proposal was then overlaid onto the CBCT scan and was used to facilitate implant planning. The aim was to provide the patient with a screw-retained bridge with access holes through the lingual aspects of the lower incisors, whilst maintaining a sound margin of safety from the lingual cortical plate. Owing to the patient's previous periodontal history, it was decided to use Standard Plus implants (Straumann) in this case. The design of this implant incorporates a 1.8mm polished collar above the active surface of the implant. This results in the implant-to-abutment junction being located 1.8mm superiorly to the bone crest.

Surgical procedure

The patient was given 400mg ibuprofen and a chlorhexidine mouth rinse before the surgery began. The procedure was carried out under intravenous sedation using midazolam.

The lower incisors were removed using periostomes and forceps. The sockets were curetted and thoroughly irrigated. A crestal incision with distal relieving incisions was made. Owing to the CBCT scan and surgical stent, only a small lingual reflection was necessary.


Implant placement was carried out using standard ITI (International Team for Implantology) protocols. Two Slactive Standard Plus implants (4.1 x 10mm, Straumann) were placed. The implants exhibited excellent primary stability with an insertion torque of greater than 35Ncm. The patient's bone quality was estimated to be type D1-2 (Lekholm & Zarb 1985). Owing to the high primary stability and good bone quality, it was decided to adopt a single-stage surgical protocol, thereby placing healing abutments over the implants. The site was closed using 5-0 polyglycolide sutures and a tooth-supported denture replacing the lower incisors was fitted. Careful examination of the denture was carried out to ensure there was no contact or transfer of occlusal load onto the implants from the denture. The patient was seen seven days after surgery for suture removal and review.

The patient healed without incident and, owing to the favourable lingual undercut of the lower teeth, was able to wear the denture comfortably during the healing process. Owing to financial reasons, the planned implant placement for the tooth UR4 site was deferred until a later date.

After eight weeks of healing, fixture-level open-tray impressions were taken in Impregum (3M ESPE) and a four-unit screw-retained bridge was fabricated. The tooth set for the denture was duplicated on the final bridge, as the patient was happy with the tooth size and shape. Owing to the previous bone loss, pink porcelain was added to the bridge to improve the emergence profile and reduce the crown lengths of the lower incisors.

The bridge was seated and torqued to 35Ncm and composite placed in the access holes. A baseline long-cone periapical radiograph was taken to serve as a baseline for bone-level measurements. The occlusion was checked, with the patient exhibiting canine guidance in excursive movements. The patient was shown how to clean under the bridge using super floss and Tepe brushes and placed on a long-term maintenance programme.

Prognosis

The bridge has a good long-term prognosis due to this patient being highly motivated and exhibiting excellent oral hygiene. She is aware of the increased risk of complications and the possibility of losing more teeth in the long run, but after having worn a denture for three months she is determined to avoid becoming a long-term denture wearer. The patient will see me at six-monthly intervals and sees a hygienist every three months for maintenance. 

For a list of references please contact Julian English at julian.english@fmc.co.uk.